

# CEPHALOMETRIC ANALYSIS OF GROWTH AND TREATMENT WITH THE STRUCTURAL TECHNIQUE: A REVIEW OF ITS BACKGROUND AND CLINICAL APPLICATION

Ib Leth Nielsen, DDS, MSc

Clinical Professor (Emeritus), Orofacial Sciences, Division of Orthodontics,  
University of California, San Francisco, USA

The aim of this review is to provide the fundamental basis and scientific evidence for the so-called “structural technique.” In this article we will discuss the benefits and challenges of this technique as well as present and compare it to the so-called “best fit” technique. Furthermore, we will introduce the three parts of the analysis, most commonly used for evaluation of growth and treatment changes. The “*structural technique*” developed by Professor Arne Björk and his associate Dr. Vibeke Skieller is the result of their longitudinal studies using metallic implants as biological markers. These studies showed that most of the information gained when using the conventional best-fit technique for analyzing growth and treatment, is incorrect. Metallic implants inserted in both the maxilla and mandible in more than 300 untreated subjects, provided the database for this new technique. Based on their findings, Björk and Skieller developed a new method for superimposing serial headfilms that they called the “*the structural technique*” that greatly reduces the previous analysis errors providing more meaningful information. Our review evaluates and demonstrates the clinical application of the “structural technique” in orthodontic patients. (*Taiwanese Journal of Orthodontics*. 30(2): 68-81, 2018)

Keywords: structural cephalometric analysis; best-fit analysis; metallic implant analysis.

## INTRODUCTION

Over the last few years there has been an important change in the cephalometric analysis of growth and treatment changes required by several orthodontic boards including the American Board of Orthodontics, the Angle Society of Europe and the European Board of Orthodontics. The new requirements include “structural superimpositions” of the treated cases presented to the Boards. This is a major change from the previous

requirement of analyzing growth and treatment changes using a so-called “best fit” superimposition. The best-fit superimposition technique was in most cases misleading and yielded incorrect information about the changes that had taken place during treatment. Current requirements of a structurally based superimposition are biologically more meaningful and include three superimpositions that demonstrate the changes during treatment as well as post treatment, an example of this technique is shown in Figure 1.

Received: May 7, 2018 Revised: May 26, 2018 Accepted: May 27, 2018

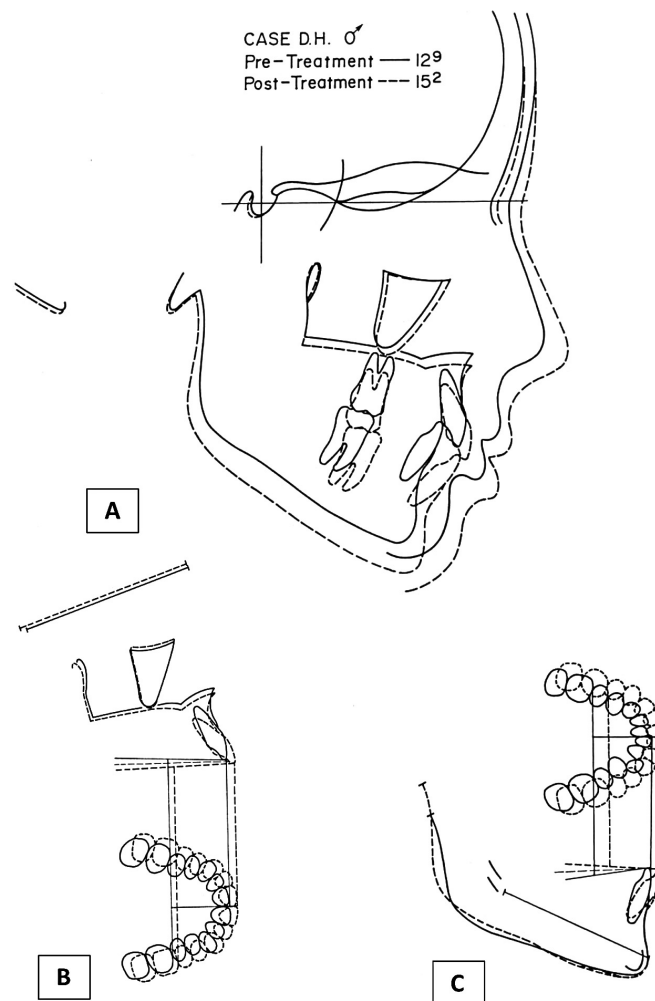
Reprints and correspondence to: Dr. Ib Leth Nielsen, Orofacial Sciences, Division of Orthodontics, University of California,  
San Francisco, CA 94143, USA

Tel: (925) 376-2072 E-mail: ibortho9@gmail.com

The superimpositions are now required to be made on biologically stable structures in the cranial base, in the maxilla, and in the mandible, as advocated by Björk et al.,<sup>1</sup> Nielsen,<sup>2</sup> and Dopple,<sup>3</sup> and scientifically supported by their studies using metallic implants, also called radiographic markers; not to be confused with TADs or modern implants to replace missing teeth. The technique is referred to as “*the structural superimposition*,” because it uses stable anatomical structures and landmarks.

In a study comparing Anatomical and Implant Superimposition, Gu and McNamara<sup>4</sup> found that the previous ABO method for superimposing serial headfilms, using a “best fit” technique, provided erroneous information concerning bone growth and remodeling. They also found that tooth movements could be “distorted significantly depending on the method of superimposition.”

Isaacson et al.<sup>5</sup> demonstrated this problem by comparing the best-fit with Björk’s implant technique.<sup>6,7,8</sup>



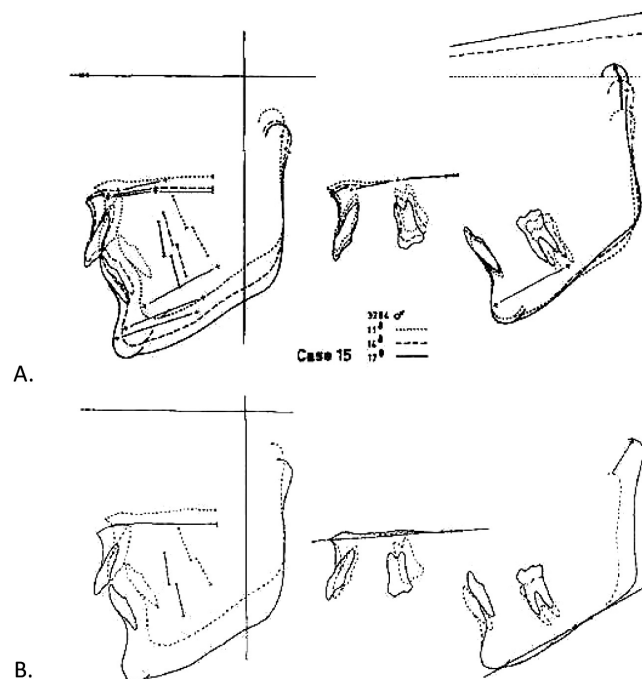
**Figure 1.** Example of “Structural Superimpositions” in a treated patient. **A** General facial growth. **B** Maxillary growth and treatment with occlusograms. **C** Mandibular superimposition with occlusograms. The patient was treated for a Class II, Div. 2 malocclusion.

They showed that for instance when the superimposition, to study mandibular changes, is made on the lower border of the mandible and registered at the symphysis, using the so-called “best-fit technique,” the teeth are often seen to move in the opposite direction to the movement seen with an implant superimposition. A further problem is the direction of condylar growth that is completely different between the two techniques (Figure 2).

The condylar growth direction, when studied with implants as in this case, is upwards and forwards; with the best-fit superimposition it is seen to be upwards and backwards. This has led to the misunderstanding that an upward-backward growth direction, as seen in Figure 2B, is the most efficient way for the mandible and chin to come forward, when in fact it is the upward

forward growth direction of the condyle that results in forward mandibular growth. The explanation is that the latter is associated with a greater vertical component, which is important for posterior face height increase that determines the direction of mandibular displacement.

In their comparative study of best-fit versus implant superimposition, Isaacson and coworkers retraced all 21 cases from Björk and Skieller’s article on “Facial development and tooth eruption: An implant study at the age of puberty.”<sup>9</sup> The process was as follows; tracings from the original article were copied, retraced and then superimposed to illustrate the differences between best fit and implant superimposition and included general facial growth, maxillary and mandibular growth and tooth movements. One of the most striking differences was in

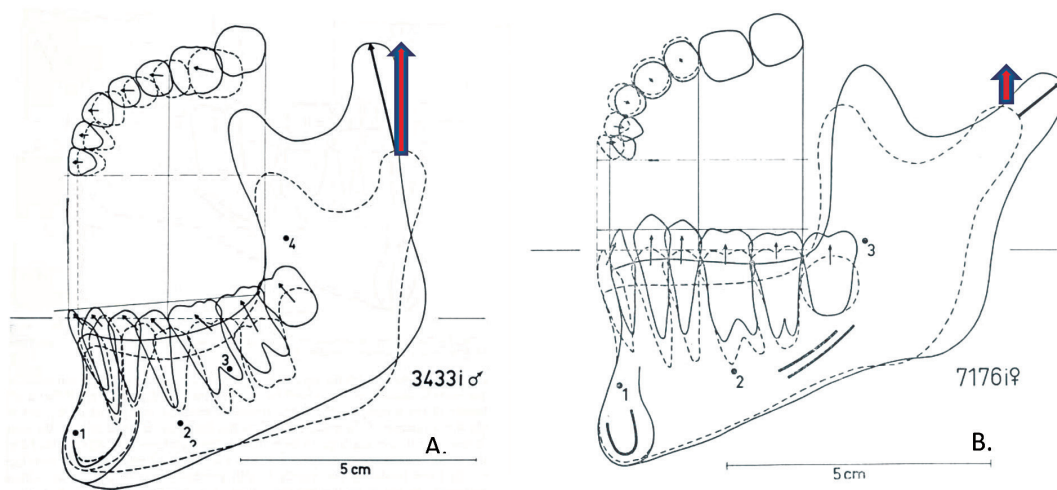


**Figure 2.** Comparison of superimpositions made on cranial base and implants in maxilla and mandible (A) with best-fit superimpositions (B) in a subject from “Facial Growth and Tooth Eruption” by Björk, A and Skieller V. *AM. J. Orthod.* 1972; vol. 62; 4; 339-383. **A** A forward-rotating case is superimposed on the anterior cranial fossa registered at sella, left. In the middle figure, the maxilla is superimposed on implants as the mandible is to the right. The mandible dashed lines represent the age of maximum growth rate. The dotted and solid lines represent 3 years before and after the maximum growth rate age. **B** Left, tracings of the dotted and solid figures but now are superimposed on the anterior cranial fossa registered at sella. Middle, the maxillae are superimposed on the palatal plane (ANS-PNS) registered at ANS. Right, the mandibles are superimposed on the mandibular plane (Gn-Go) registered at Gn. (Isaacson. R. J., Worms, R. W. Speidel, M. *AJO*; vol. 70; no. 3, 1976, Permission Elsevier)

the actual tooth movements in both maxilla and mandible, but there were also distinct differences in the growth direction of the condyles. Figure 2A and B demonstrate the two different superimpositions in a subject seen side by side (Case 15), and it can be seen that the teeth move quite differently between the two analyses. The individual superimpositions on maxilla and mandible, seen in Figure 2, demonstrate the tooth movements within the maxilla and mandible that clearly are very different. On the implant superimposition the lower incisors move forward or proclined slightly (Figure 2A), whereas on the “best fit” superimposition they move posteriorly (Figure 2B). Differences can also be seen with respect to the lower molars that with best-fit superimposition move distally whereas with implants they move mesially. It is an interesting fact that it took so many years for the “structural superimposition,” despite numerous well-documented implant studies, to finally become the recognized and

recommended method for superimposing serial headfilms. However, despite the recent changes in board examination requirements, there is still work to be done in order to achieve a more precise analysis of the molar positions on the headfilm and also their movement during treatment. It is notoriously difficult to precisely determine molar positions on the lateral headfilm by simple visualization. In a recent study we presented a new method for achieving a more precise determination of the first molar position by using measurements from occlusograms.<sup>10</sup>

The difference between a best fit and an implant superimposition is especially pronounced during the most active growth period at puberty, which is when most patients are treated. In cases where the mandible shows pronounced forward or anterior growth rotation these differences are more noticeable. Remodeling changes typically include apposition of bone under the anterior half of the mandible and resorption of the lower posterior



**Figure 3.** Variations in mandibular condylar growth direction, tooth movement and modeling of the mandibular lower border. The red arrows indicate the effective vertical component of condylar growth. The period of growth includes six years around puberty. From Björk, A. Variations in the growth pattern of the human mandible: Longitudinal radiographic studied by the implant method. *J. Dent. Res.* 1963; v42; 1; 400-411.<sup>1</sup>

border of the mandible. Both changes are adaptations to the masticatory muscles that are attached to the mandible. These remodeling changes vary depending on facial types as illustrated by two examples from Björk's early implant studies, seen in Figure 3.<sup>1</sup> Note the differences in modeling between the two more extreme types of mandibular growth and also the difference in condylar growth direction and amount. These remodeling changes relate to changes in position of the mandible within the soft tissue matrix during the growth period and are in response to changes in muscle length and attachment.<sup>11</sup> The tooth movements seen clearly differ between the two superimpositions. In the case seen in Figure 3A, the incisors move forward, and the molars migrate mesially, whereas in the case in Figure 3B the incisors erupt posteriorly and the molars vertically with no forward movement.

The resorption of the lower border of the mandible is a biological response to the rapid lowering of the mandibular ramus resulting from condylar growth. One might then ask what causes this resorptive modeling to take place? The best understanding we have, is that the muscle fibers of the pterygo-masseteric sling attached to the mandibular ramus are not capable of lengthening fast enough to keep up with the rapid growth changes, thus affecting these changes to maintain their insertion in the bone. The opposite muscle-bone reaction takes place anteriorly in cases with forward growth rotation of the mandible. Below the symphysis, along the posterior border of the symphysis and along the anterior part of the lower border of the mandible, bone is often added in order to maintain the insertion of the muscles. The result over time is a continuous thickening of the inferior lower and posterior border of the symphysis, and of the anterior lower border of the mandible (Figure 3A). Note that there is no apposition on the anterior part of the symphysis or the chin area, so this area can safely be used for superimposition. The tracing of the mandible of the subject on the right in Figure 3B, on the other hand, shows

a different direction of condylar growth. The condylar growth direction in this case is upwards and backwards, and the amount of vertical growth (indicated by an arrow) is much less than in the case seen in Figure 3A. As a result, there is little or no need for lower border modeling. Björk recognized early on that facial growth was complex and that modeling changes varied between facial types.<sup>6,7,8</sup> He also found that these anatomical changes could only be studied in detail by using a technique that eliminated the influence of surface modeling of the bones, and began using small metallic implants or radiographic markers that could be embedded in the jaw bones. As there is no interstitial bone growth, these markers are permanent and remain stable over time. In the following we will describe the three most typically used superimpositions to demonstrate facial growth and treatment changes.

## GENERAL FACIAL GROWTH EVALUATION


The most commonly used superimposition, to determine the general facial growth and treatment changes, is one that is made on structures in the cranial base. This area has been preferred for many years, and even in anthropology studies. In modern times it has been shown by *Melsen* that growth changes in the anterior and part of the middle cranial base seize early in life at around age 6-7.<sup>12</sup> In the past, superimpositions were usually made along the *nasion-sella* line and registered at *sella*. The studies by *Björk* et al., using the implant technique clearly showed, however, that during growth *nasion* undergoes local modeling changes that can shift this landmark up or down making its use questionable.<sup>11</sup> A similar problem is present with respect to *sella*, that has been demonstrated by *Melsen* who reported, from her histological studies of the cranial base, that there is a continuous shift, during the growth period, in the position of the center of *sella* over time. She found that this reference point moves downward and backwards at a rate of about 1-2 mm per year, rendering it of less value in a superimposition. The

illustration in Figure 4 shows the changes of the posterior wall of *Sella Turcica* that take place over time. Walker’s point is also indicated, an anatomical landmark located at the intersection (arrow) of the anterior wall of sella and the anterior clinoid process, this point has been shown to be stable over time.

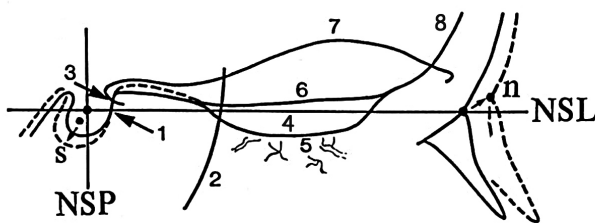
As a result of these changes the nasion-sella line can shift or rotate to such an extent that it incorrectly

influences the interpretation of the growth directions of the maxilla and mandible, and makes a superimposition using the conventional nasion sella line unreliable.<sup>12</sup>

To circumvent these problems of local remodeling, Björk et al. recommended using superimpositions made on stable structures in the anterior and median cranial base.<sup>11</sup> The structures they advocate are shown in Figure 5 and listed in Table 1.




**Figure 4** “Sella Turcica” with arrow indicating Walkers point and the anterior clinoid process. Note the resorption of the posterior wall of sella.



**Figure 5.** Showing the stable structures in the anterior and median cranial base used for superimposition.

**Table 1.** Stable structures in the cranial base.

STABLE STRUCTURES IN THE CRANIAL BASE	
■	Anterior wall of Sella Turcica (1)
■	Anterior contour of median cranial fossa (2)
■	Walker’s point (3)
■	Cribriform plate (4)
■	Ethmoid bones (5)
■	Median border of orbital roof (6)
■	Orbital roof (7)
■	Inner part of frontal bone (8)



**Figure 6.** Nasion-sella line (NSL), and the nasion sella perpendicular line (NSP). Sella center (S) is determined by dividing the distance between the anterior and posterior wall of sella.

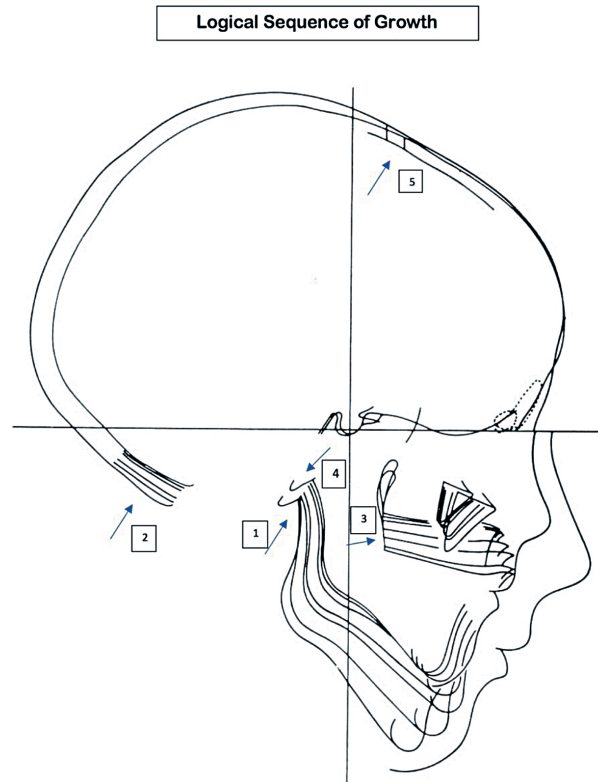
To create a general superimposition the following sequence should be followed. The *nasion-sella (NSL)* line is marked on the initial headfilm, or tracing thereof, as a line through the geometric center of *sella turcica (S)*. The center of *sella* is determined by dividing the antero-posterior distance and the vertical height of *sella* (Figure 6).

Anteriorly the anatomical reference point *nasion (N)* is used, but only on the first film in a series. The procedure is as follows. A line is drawn through these reference points and a vertical line NSP, perpendicular to the NSL line, is constructed through sella center. The two original reference points, *sella* and *nasion* are only used on the initial headfilm and in order to establish the reference lines, NSL and NSP. It is also important to remember that the NSL line goes through the structures that are stable and used for superimposition. After aligning the second film on the stable structures the initial the nasion-sella line is traced onto the second film, or any subsequent headfilms in a similar way. Where the transferred or new, second nasion-sella line cuts across the area of the previous nasion location, that point is now referred to as “*transferred nasion.*” With respect to *sella* that landmark remains unchanged in relation to the anterior wall of *Sella Turcica*. It is not uncommon to observe that the original

*nasion* reference point has shifted up or down slightly, but the error it would have caused if used, has now been eliminated from the superimposition. By using this technique, measurements made to the nasion-sella line now are made to stable structures, rather than a changing reference system.

A well-known problem, when making a general superimposition, is the error resulting from the structures used being too close together. This can typically result in rotational errors and can yield an incorrect analysis of the changes, such as the chin going either too far back or forward. This technique reduces this problem to a minimum, and especially if a second principle for superimpositioning serial headfilms is employed. In order to solve this rotational problem, Björk and Skieller (1983), recommended observing a “*Logical Sequence of Growth Changes*” of specific anatomical structures after the headfilms have been aligned.<sup>11</sup> So what does this mean? Their recommendation is to observe a logical sequence of growth changes when analyzing two or more headfilms in a series. In other words, the analysis should be based on two important principles:

- (1) Superimposing on stable structures**
- (2) Observe a logical sequence of growth changes**



**Figure 7.** Control tracing showing landmarks with a logical sequence of growth changes. These include: **1)** Point Articulare, moves downward and posteriorly, **2)** Outer surface of the occipital bone-moves in an outward direction, **3)** Pterygo-maxillare (posterior nasal spine-PNS), moves mostly straight vertically, **4)** Basion, **5)** Fronto-parietal suture moves posteriorly.

As it turns out, this second principle can, to a great extent, reduce or eliminate rotational errors and improved the results of the analysis, when compared to previous techniques. Example of the structures that can be used is seen in Figure 7.

What information can we gain from the general superimposition? When superimpositions are correctly done, they can be very helpful both during orthodontic treatment and after treatment. Most superimpositions are made following treatment and in some instances after retention. The information we can gain includes but is not limited to the following:

### The General Facial Growth Tracing

What does it tell you?

- Direction of maxillary and mandibular growth
- Amount of maxillary and mandibular growth
- Changes in inclination and position of the anterior and posterior teeth in relation to the face
- Changes in the occlusal plane

What does this superimposition not show?

- Rotational changes of the jaws
- Transverse changes of the dental arches
- Tooth movements in maxilla and mandible
- Possible anchorage loss



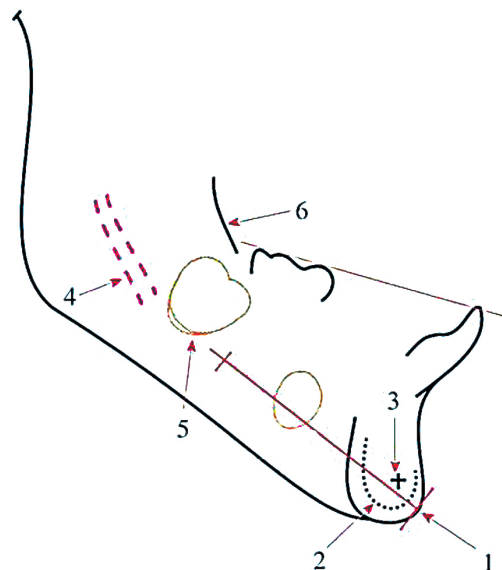
## MANDIBULAR GROWTH AND TREATMENT CHANGE

Important details about the changes during orthodontic treatment cannot be gained just from the general superimpositions. For instance, the amount of condylar growth and rotation of the mandible, as well as the tooth movements within the mandible can only be studied on a mandibular superimposition. So once again the implant studies help us achieve a more correct appreciation of the changes. When looking at the two mandibles shown in Figure 3, it can be seen that structures such as the inner lower border of the mandibular symphysis, the anterior part of the chin and the mandibular canal have been emphasized. This was done by Björk (1963) to indicate that these structures repeatedly turned out to be stable during growth in his subjects, and in relation to the metallic implants. This is

due to the fact that there is no interstitial bone growth so neither his implants nor these structures changed during growth.

Further observation has also shown that the inferior part of developing tooth buds (no. 5 in Figure 8) also remain stable until the time root formation begins. The following illustration Figure 8 shows the structures used for a so-called “*structural superimposition.*”

The practical procedure for a mandibular superimposition is to first register the jaws at the chin. Then the second film is rotated upward or downward with progressively less movement until the mandibular canals are aligned. If two canals are visible the difference is divided evenly. In cases where there are developing molars, second or third, these can also be used to improve the precision of the alignment, but only the inferior part of the tooth buds can be used and only until root formation begins.

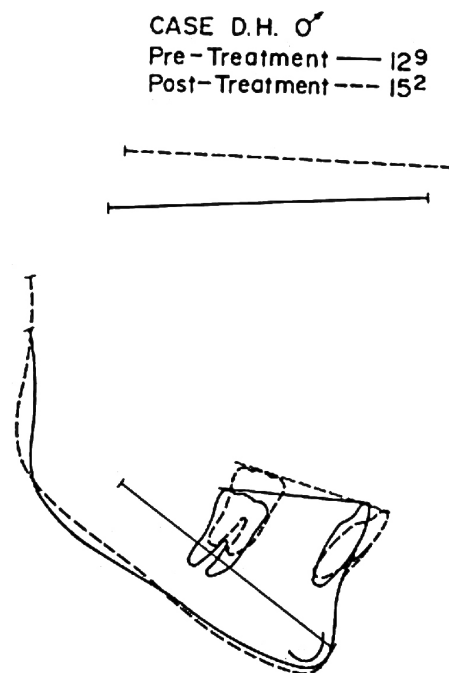


**Figure 8.** Structures used for mandibular superimposition. (1) Anterior outline of the chin, (2) Inner lower border of symphysis, (3) Trabecular structures within the symphysis, (4) Mandibular canal, (5) Inferior part of developing tooth bud. Not included is the anterior border of the mandibular ramus (6) that serves as a structure to observe for a logical sequence of growth changes.

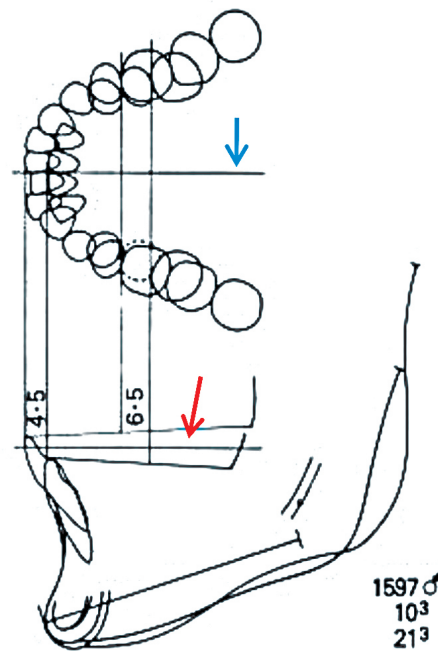
The anterior outline of the ramus (no. 6 in Figure 8) can serve as a structure that should change in a logical way; a structure that is not stable as long as there is mandibular growth, and either changes in a posterior direction, or not at all. Typically subjects with upward forward condylar growth often have no resorption of the anterior border of this structure, an example can be seen in Figure 3A. Once, the mandibles have been superimposed traced or digitized, the incisors and the lower occlusal planes are placed. By using occlusogram measurements from scanned study casts, the molars can now be positioned in their correct locations.<sup>10</sup> The nasion-sella lines at the two stages are usually included in the superimposition to indicate the amount and direction of mandibular rotation during the treatment period. An example of a superimposition of two mandibles,

representing the before and after treatment stages, in a treated subject is seen in Figure 9. The line from the chin and posteriorly towards the molars is a so-called reference line. This line is arbitrarily placed in the mandible on the first headfilm and then transferred to subsequent films after superimposition on the stable structures. On a general superimposition the same line will now show any rotational changes that occurred.

A further development of the mandibular superimposition includes the occlusograms from before and after treatment. This superimposition provides additional details about the changes during treatment and is made in the following way. The two headfilms are traced and superimposed similarly to what was seen in Figure 9. However, the molars are not initially included but added afterwards. After the incisors and



**Figure 9.** Mandibular superimposition on stable structures in the mandible. Note the rotation of the jaw by the change in inclination of the nasion-sella lines. The mandibular occlusal plane rotated opposite to the mandible during this period.



**Figure 10.** Mandibular superimposition on stable structures with occlusograms aligned to the incisors and showing forward movement of the dentition during treatment. The molars moved mesially 6.5 mm and the incisors came forward 4.5 mm. No transverse changes were noted.

the two mandibular occlusal planes have been drawn, the difference between these is divided and a so-called occlusal plane bisector ( $OL_{Bi}$ ) is constructed, as seen in Figure 10.

The mandibular superimposition with occlusograms offers additional important information about the dental arch changes and can only include two stages. The first step in the superimposition process is similar to the conventional mandibular superimposition, without the molars. The two occlusal planes (pre and post) are then divided and an occlusal plane bisector is traced, here indicated by a red arrow. Two parallel vertical lines are now constructed from the labial of the lower incisors at ninety degrees to this bisector ( $OL_{Bi}$ ), and at a certain distance that later allows the two occlusograms to be drawn so as not touch the occlusal planes. Then a common midline (blue arrow) is constructed at ninety degrees to

the incisors tangent lines. Then the two occlusograms are drawn beginning at the anterior teeth. Finally, vertical lines from the mesial of the first molars are constructed at ninety degrees to the midline and extended to the respective occlusal planes.

The benefits of including the two occlusograms are several. First, it yields additional information about the dental arch changes and shows, for instance, how crowding or spacing was been alleviated. Second, it permits a precise location of the first molars and shows the movement of these teeth as well as the incisors in all three planes of space. Third, it shows any midline correction that took place during treatment and further demonstrates transverse arch changes that occurred. To summarize the information that can be gained from mandibular superimpositions:

## Mandibular Superimposition

(What does it tell us?)

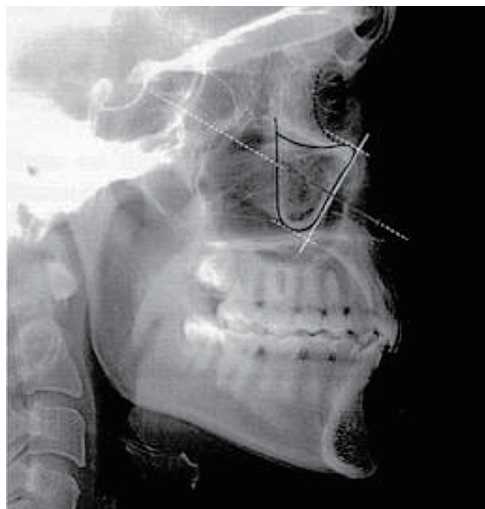
- Amount and direction of condylar growth at articulare (ar)
- Rotations of the mandible relative to cranial base
- Molar and incisor eruption and mesio-distal movements
- Molar and incisor inclination changes
- Mandibular occlusal plane change
- Modeling (remodeling) of the lower jaw

## MAXILLARY GROWTH AND TREATMENT CHANGES

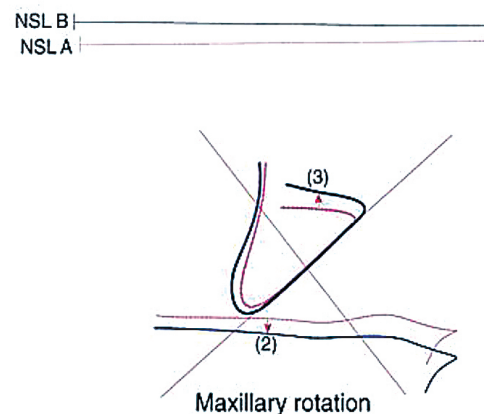
For many years, maxillary superimposition has been a challenging procedure, and its accuracy has often been questioned especially in orthodontic patients where no implants had been inserted. Several attempts have been made to improve the reliability, but none have been reliable until Björk in 1977 suggested to use a structural superimposition based on the following approach.<sup>13</sup> From

their implant studies Björk and Skieller had found that the anterior outline of the zygomatic process of the maxilla was stable when implants had been placed in that location.

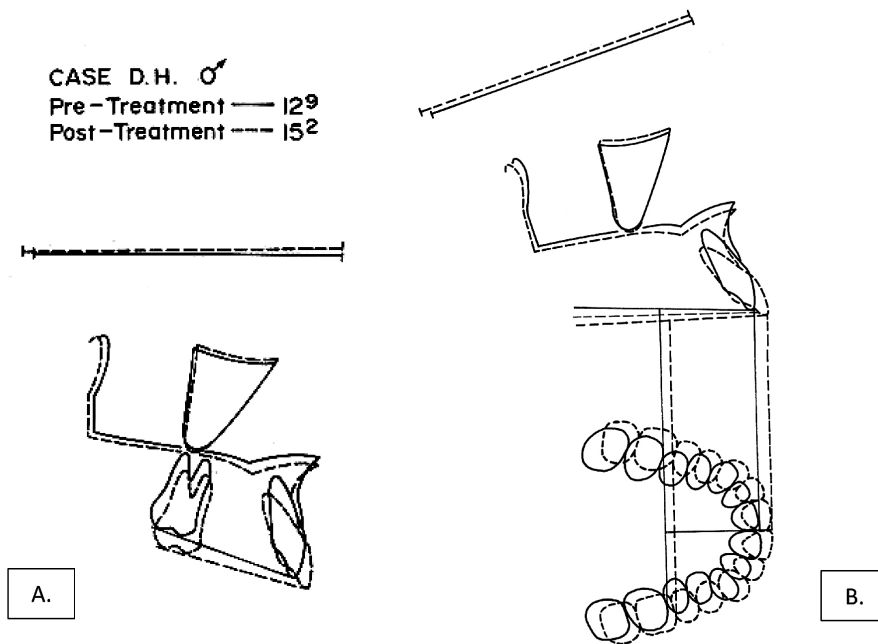
Additionally they had measured the surface changes within the maxilla over a period of 16 years and found that there was a certain relationship between apposition at the orbital floor and resorption of the nasal floor that could be broken down to an average ratio of 3:2.<sup>13</sup> As a result of their observations, they recommended to align the headfilms on the anterior outline of the zygomatic process or “Key Ridge” (Figure 11), then slide the second film up and down along this structure until there is slightly more apposition on the orbital floor than resorption (3:2 ratio) of the nasal floor. Now lock the tracings together and trace the structures, as seen in Figure 12. Our statistical analysis of cases comparing structural, implant and best fit has shown that the recommended, “structural superimposition” is close if not identical to an implant superimposition.<sup>2</sup>



**Figure 11.** Lateral headfilm with the zygomatic process and reference lines indicated.



**Figure 12.** Schematic illustration of the zygomatic process and the alignment of two tracings on the anterior outline of the process. Note the apposition indicated (3), and the resorption of the nasal floor (2). There is greater resorption anterior than posteriorly of the nasal floor. The changes in the nasion-sella line indicate the direct of rotation of the maxilla.



**Figure 13.** Maxillary “structural superimposition” on anterior outline of the zygomatic process. **A** Demonstrate the superimposition without occlusogram. **B** Shows superimposition of pre and post treatment headfilm including the respective occlusograms.

The following two superimpositions can now be made on the stable structures as seen in Figure 13. The superimposition (B) has been adjusted to allow the occlusal planes to be horizontal.

### Maxillary Superimposition

(What does it tell us?)

- Amount and direction of maxillary growth—vertical and horizontal
- Rotations of the maxilla relative to cranial base
- Molar and incisor eruption and mesio-distal movements
- Molar and incisor inclination changes
- Dental arch width and midline changes
- Maxillary occlusal plane changes
- Modeling (remodeling) of the nasal and orbital floors

### SUMMARY

In this review article, we have introduced and discussed the biological basis for the so-called “*structural superimposition*” of serial headfilms. This technique provides a more biologically meaningful approach to cephalometric analysis of growth and treatment changes than the previously used *best-fit* techniques.<sup>14,15</sup> “Structural superimposition,” is primarily based on the results of many years of studies of facial growth in subjects where metallic implants had been inserted in the jaws (Björk). Most of the subjects in his study did not receive orthodontic treatment so they have served as a unique

source of information about the variations in normal facial growth and development, but also provided the basis for this new technique for superimposing headfilms.

The "structural technique," we have presented in this article has now been adopted by several orthodontic boards, as well as components of the Angle Society around the world, and it seems to be the most meaningful and reliable method for analyzing growth and treatment changes over time.

## REFERENCES

1. Björk, A. Variations in the growth pattern of the human mandible: longitudinal radiographic study by the implant method. *J Dent. Res.* 1963; 42:400-411.
2. Nielsen, I. L. Maxillary superimposition: A comparison of three methods for evaluation of maxillary growth and treatment change. *Am. J. Orthod. Dentofac. Orthoped.* 1989; 96:422-431.
3. Doppie, M. D., Ward, M. D., Joondeph, D. R., Little, R. M. An investigation of maxillary superimposition techniques using metallic implants. *Am. J. Dentofac. Orthoped.* 1995; 105(2):161-168.
4. Gu, Y. and McNamara, J. A. Jr. (Cephalometric Superimpositions: A Comparison of Anatomical and Metallic Implant Methods. *Angle Orthod.* 2008; Vol. 78(6):967-976.
5. Isaacson. RJ, Worms, F W, Speidel, TM. Measurement of tooth movement. *Amer J. Orthod.* 1976; vol. 70(3): 290-303.
6. Melsen, B. The Cranial Base. The postnatal development of the cranial base studied histologically and on human autopsy material. *Acta Odontol. Scan.* 1974; 32:suppl. 62.
7. Björk, A. Sutural growth of the upper face studied by the implant method. *Acta Odontol Scand.* 1966; 24:109-129.
8. Björk, A. The use of metallic implants in the study of facial growth in children: method and application. *Am. J Phys. Anthrop.* 1968; 29:243-254.
9. Björk, A. Skieller, V. Facial development and tooth eruption: An implant study at the age of puberty. *Amer J. Orthod.* 1972; 62:339-83.
10. Nielsen, I. L. Yao, CCJ. Do we really know where the molar teeth are on the lateral headfilm? A recommendation for a more precise way to locate the molars on the lateral headfilm. *Taiwanese, J. Orthod.* 2018; 30(1):4-11.
11. Björk A, Skieller V. Normal and abnormal growth of the mandible. A synthesis of longitudinal cephalometric implant studies over a period of 25 years. *Eur. J. Orthod.* 1983; 5(1):1-46.
12. Houston, W. J. B. , Lee, R. T. Accuracy of different methods of radiographic superimposition on cranial base structures. 1985; *Eur. J. Orthod.*; 7(2):127-135.
13. Björk, A., Skieller, V. Growth of the maxilla in three dimensions as revealed radiographically by the implant method. *Br. J. Orthod.* 1977; 4:53-64.
14. Tong, YY., Lai, E., Chen, YJ., Yao, CCJ. A review of general and mandibular superimposition. *Taiwanese J. Orthod.* 2006; 18(3):10-17.
15. Wen, YR., Lai, E., Chen, YJ., Yao, CCJ. A review for maxillary superimposition. *Taiwanese J. Orthod.* 2006; 18(3):24-30.